

# Intense pulsed light source for treatment of facial telangiectasias

Peter Bjerring, Kaare Christiansen & Agneta Troilius

## Authors:

**Peter Bjerring MD, MSc (Med)**  
Department of Dermatology  
University Hospital of Aarhus  
Aarhus, Denmark  
**Kaare Christiansen MSc (EE)**  
Private Hospital Molholm  
Veje, Denmark  
**Agneta Troilius MD, PhD**  
Department of Dermatology,  
University Hospital,  
Malmoe, Sweden

Received 2 March 2001

Revised 17 September 2001

Accepted 8 October 2001

## Keywords:

dual mode filtering – intense pulsed light source – IPL – purpura – telangiectasias – treatment

**OBJECTIVE:** The purpose of this clinical study was to evaluate the effectiveness of the first intense pulsed light source (IPL) with dual mode light filtering for treatment of facial telangiectasias, and to evaluate the incidence of adverse effects, including purpura, pigmentation and scars.

**MATERIALS AND METHODS:** Twenty-four patients with facial telangiectasias were treated between one and four times with a new IPL system. This system differs from previous IPLs by eliminating wavelengths longer than 950 nm, which would otherwise lead to non-specific heating of tissue water. The treatments were performed at one-month intervals. Two

months after the last treatment, the clinical effect was evaluated from close-up photographs.

**RESULTS:** After one to four IPL treatments (mean: 2.54; SD: 0.96) for facial telangiectasias, 79.2% of the patients obtained a more than 50% reduction in number of vessels, and 37.5% obtained between a 75% and 100% reduction. Moderate erythema and oedema were the only adverse effects of the treatment. No purpura was registered and no long-term adverse effects such as scars or pigmentary disturbances occurred.

**CONCLUSIONS:** An IPL with dual mode filtering is efficient and safe for treatment of facial telangiectasias. J Cosmetic & Laser Ther 2001; 3: 169–173

## Introduction

Early treatments for vascular lesions were performed with argon lasers, copper vapour lasers and krypton lasers. These lasers emit very long pulses, in the range of 100–300 ms, and wavelengths ranging from 510 nm to 578 nm. These wavelengths are absorbed by the skin at a very short distance from the surface (300–500  $\mu\text{m}$ )<sup>1,2</sup> due to a relatively high absorption in the melanins, and the combination of very long pulse durations (200–300 ms) and the strong tissue absorption generated a high incidence of both immediate and subsequent adverse effects such as skin atrophy, scarring, and pigment disturbances.

Today, the most common lasers for the treatment of facial telangiectasias are the pulsed dye, diode, and frequency-doubled Nd:YAG lasers. Due mainly to their short pulse durations (0.45–1.5 ms), these lasers affect the vessels more selectively<sup>3</sup> and hence treatments are more safe and efficacious.<sup>4</sup>

The short pulse duration (0.45 ms) of the dye laser reduces the risk of severe long-term adverse effects, but also leads to vessel disruption and visible purpura. This is often very disturbing for the patients.

Light absorption in haemoglobin occurs at wavelengths of 412 nm and up, but due to a strong concurrent melanin absorption in the epidermis, only longer wavelengths reach deeper vessels in the skin.<sup>5</sup> The most effective wavelength range is in the spectral range from 540 to 650 nm, incorporating the haemoglobin absorption peaks at 542 nm and 577 nm. For thicker vessels (0.3–0.5 mm) Kienle et al<sup>6</sup> predicted – based on the Monte Carlo

Correspondence: Peter Bjerring, Department of Dermatology, Marselisborg Hospital, DK-8000 Aarhus, Denmark.  
Tel: (+45) 40634878; Fax: (+45) 87415123

## Original Research

computer simulation method – that wavelengths of about 600 nm would be optimal in order to achieve selective photothermolysis. Broadband intense light sources (intense pulsed light (IPL) systems) are able to emit continuous light spectra which contain significant proportions of light at wavelengths from 550 nm or 570 nm to 1200 nm, thereby covering all clinically significant absorption peaks.

The dimensions of the telangiectatic vessels vary from 10  $\mu\text{m}$  to 400  $\mu\text{m}$  and the mean diameter of the vessels is related to the colour of the lesion. Diffuse pink lesions generally have smaller diameters (10–20  $\mu\text{m}$ ) than purple lesions (50  $\mu\text{m}$ ), and the larger vessels will normally be located deeper than pink and red lesions.<sup>7</sup> The diameters of visible telangiectatic vessels vary between 100 and 400  $\mu\text{m}$ , and mathematical calculations predict that the ideal pulse duration for the treatment of these telangiectasias will be 0.5 ms to 30 ms, depending on the actual vessel diameter. Dierickx et al<sup>8</sup> and Dover and Arndt<sup>9</sup> found – based on a histological assessment of vessel injury in port-wine stains – that the ideal laser pulse duration would be between 1 ms and 10 ms, depending on the diameter of the vessel.

In contrast to most lasers, the pulse duration of IPL systems can be varied over a very broad range of time. For treatment of facial telangiectasias, pulse durations which match the relaxation time of the ectatic blood vessels (2 ms to 30 ms) can easily be generated.<sup>10,11</sup>

The purpose of the present clinical study was to evaluate the efficacy and safety of the first IPL with dual mode light filtering which restricts the emitted wavelengths to the 555 nm to 950 nm range for the treatment of facial telangiectasias.

## Patients and methods

### Patients

The study included 24 patients, 19 females and 5 males, with facial telangiectasias belonging to Fitzpatrick's skin types 1–3 (average: 2.0; SD: 0.5). The mean age was 47.8 years (SD: 9.5 years). All volunteers gave their written

informed consent, and the Regional Ethics Committee approved the study.

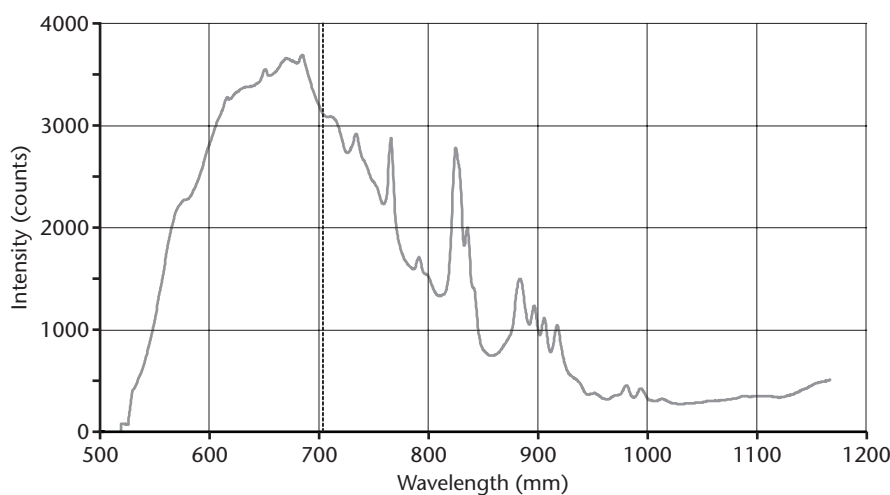
### Intense pulsed light source

A newly developed IPL (Ellipse Flex, Danish Dermatologic Development, Hoersholm, Denmark) was used for the treatments. Dual mode filters restricted the emitted light to the wavelength band from 555 nm to 950 nm, with a median wavelength of the power spectrum at 705 nm (Figure 1). The present IPL differs from previous IPL systems by inhibiting wavelengths longer than 950 nm. Longer wavelengths are strongly absorbed by water, which leads to non-specific heating of tissue water.

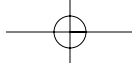
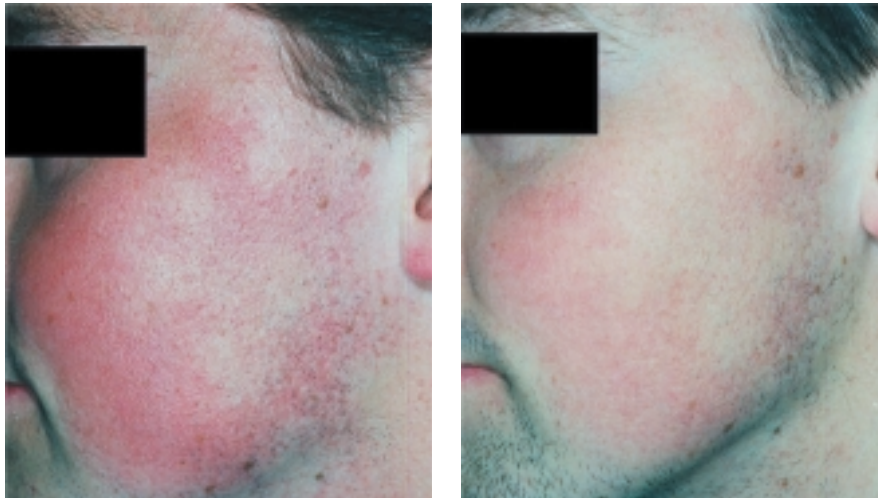
The light fluency levels normally emitted from IPLs range from 20 to 50 J/cm<sup>2</sup> in order to achieve clinical effects on facial telangiectasias; however, the present IPL system emits clinically effective light pulses with fluency levels of between 10 and 26 J/cm<sup>2</sup>. The filtered light is guided to the skin surface by a 10  $\times$  48 mm light-conducting crystal. The optical coupling between the crystal and the skin surface is optimised by application of a thin layer of optical index-matching hydro-gel. Care was taken to ensure that no mechanical pressure was applied to the skin surface by the IPL system's optical light guide: compression or removal of the target blood from the treatment area during treatment will reduce the light absorption and hence the clinical effect.

### Treatment procedure and clinical evaluation

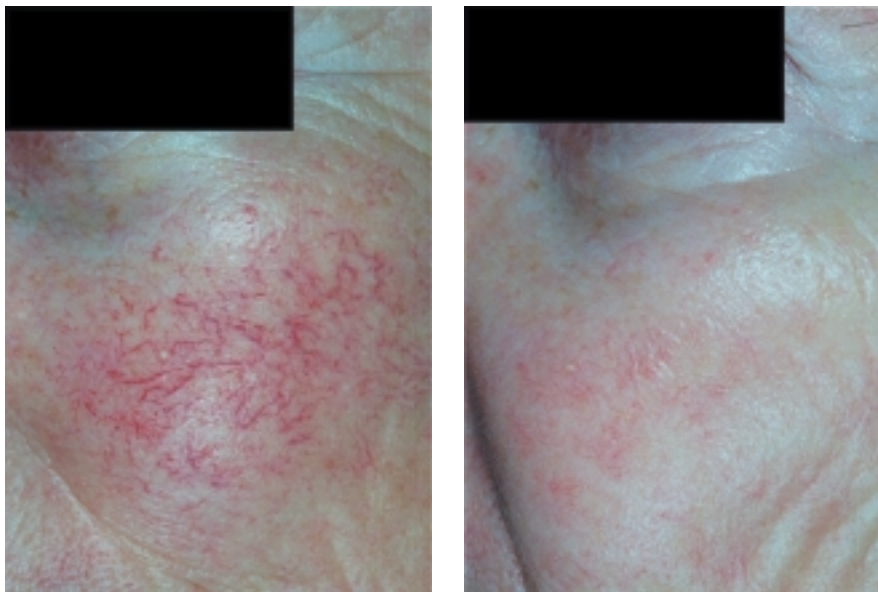
The 24 patients received between one and four IPL treatments at one-month intervals. Before the treatments, the areas to be treated were covered with a thin layer of transparent hydro-gel (Optical Coupling Gel, DDD Hoersholm). The light fluency was individually adjusted in order to reach the clinical endpoint at which the vessels changed to a slightly bluish colour for a few seconds immediately after the light exposure, followed by a quick return to the normal and more bright red colour. Fluencies used for the treatments ranged from 13 to 22 J/cm<sup>2</sup> (average: 17.1 J/cm<sup>2</sup>; SD: 2.0 J/cm<sup>2</sup>). The pulse



**Figure 1**  
Spectral distribution of energy measured at the skin surface. The median wavelength of the total power spectrum is indicated (dashed line at 705 nm).

*Original Research*

**Figure 2**  
Patient with diffuse erythema without significant visible vessels before and after four IPL treatments.



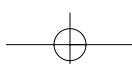
**Figure 3**  
Patient with visible telangiectasias before and after four IPL treatments.

durations were adjusted to match the relaxation time for the vessels. For diffuse redness without any large, visible vessels present (Figure 2), pulse durations of 10 ms were used. For visible thin and thick vessels (Figure 3), pulse durations of 15 ms and 30 ms respectively were used. No topical, local or general anaesthesia was used during any of the treatments.

Clinical examination and close-up photography were performed before each of the treatments and at the follow-up visit. Evaluation of the treatment results was performed by a trained dermatologist in a blinded fashion using standardised photographs. The clinical

outcome was evaluated as the percentage of clearance for visible vessels and diffuse erythema separately. The final cosmetic result was subsequently calculated as the mean of these two results. The number of treatments offered to each patient was defined by one of the following endpoints: (1) a satisfactory clinical result was obtained, or (2) no further improvement could be observed.

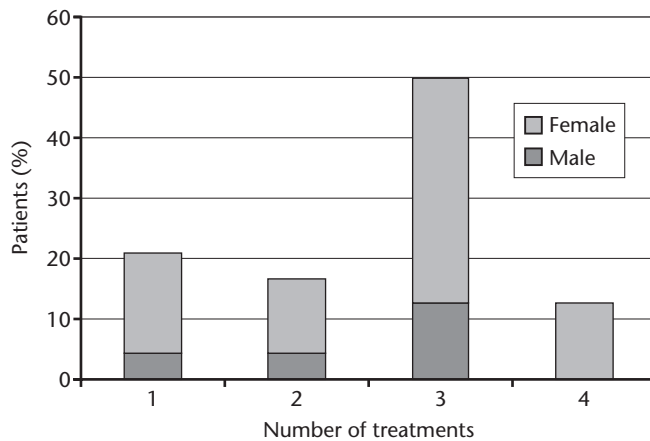
The following adverse effects were evaluated: purpura, hypopigmentation, hyperpigmentation, atrophic scarring, hypertrophic scarring (two months after the last treatment). All side effects were evaluated on the following scale: 0 for none, 1 for slight, 2 for moderate, or 3 for severe.



## Original Research

### Results

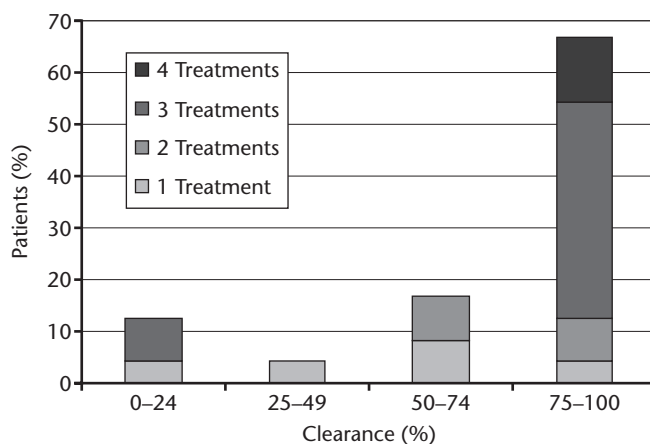
The number of treatments received by each patient is shown in Figure 4. Five patients (20.8%) received only one treatment; four (16.7%) had two treatments; 12 patients (50%) had three treatments; and three patients (12.5%) were treated four times. The mean number of treatments was 2.54 (SD: 0.96). The patients received between 4 and 54 shots per treatment session (mean: 22.1; SD: 8.8).



**Figure 4**  
Distribution of number of treatments for IPL treatment of facial telangiectasias.

### Reduction of visible vessels

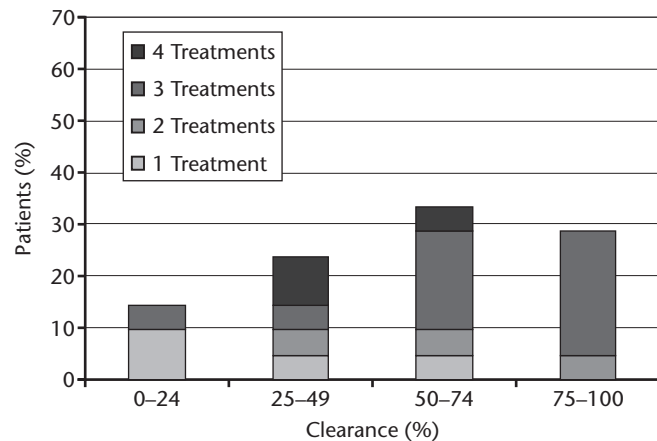
All 24 patients obtained a reduction in visible vessels. Of them, 83.4% obtained more than 50% clearance, and 66.7% more than 75% clearance (Figure 5).



**Figure 5**  
Clearance of visible facial telangiectasias after one to four IPL treatments.

### Reduction of diffuse erythema

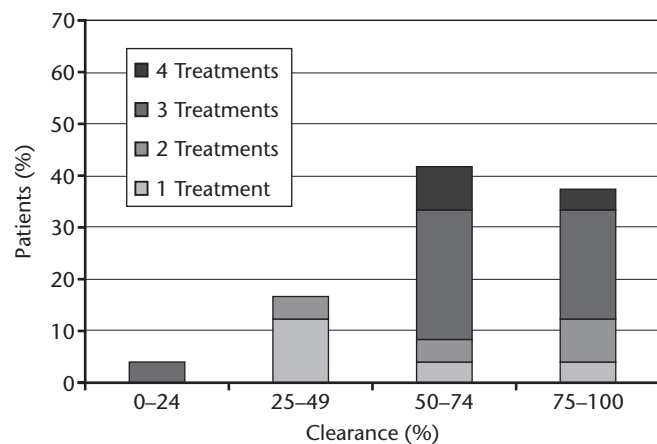
Diffuse erythema was reduced in 19 out of 21 patients (90.4%). Of all 24, 61.9% obtained more than 50% clearance, and 28.6% more than 75% clearance (Figure 6).



**Figure 6**  
Clearance of diffuse erythema after IPL treatment for facial telangiectasias relative to number of treatments.

### Final cosmetic result

All 24 patients obtained reduction in either visible vessels or diffuse erythema. Of them, 79.2% obtained more than 50% global cosmetic clearance, and 37.5% obtained more than 75% global clearance (Figure 7). The average cosmetic clearance was found to be 62.7% (SD: 23.0%).



**Figure 7**  
Combined clinical outcome following between one to four IPL treatments.

### Adverse effects

No incidence of purpura was observed, but all patients experienced variable degrees of oedema and erythema. While erythema was present immediately after the treatment, oedema often developed during days 1 and 2 after the treatment, lasting up to five days. Hypertrophic or atrophic scars or pigmentary disturbances did not occur. In addition to the effect on skin vessels, treatments performed on hair-bearing skin also resulted in permanent damage to brown or black terminal hair follicles.

## Discussion

Vascular treatments performed with the IPL technology<sup>11–13</sup> has shown results comparable to those obtained by the frequency doubled Nd:YAG laser. Dummer et al<sup>14</sup> used a long-pulsed frequency-doubled 532 nm Nd:YAG laser in 42 patients, and found that 28.6% of the patients obtained 80% clearance or higher, and 78.5% obtained more than 50% clearance. These results are comparable with the results obtained in the present study, in which 37.5% obtained 80% clearance or higher and 79.2% obtained more than 50% clearance. However, treatments with the frequency doubled Nd:YAG laser are painful, and Dummer et al reported that the use of local anaesthesia was needed in six patients.

In the present study we obtained a higher efficacy in IPL treatment of telangiectatic vessels of the visible type (large vessels) than in diffuse erythema (small vessels). This might be due to the relatively long pulse durations used (>10 ms). In order to match the pulse duration to the vessel relaxation time for diffuse erythema vessels with diameters as thin as 10–50 µm, pulse durations should be in the order of 0.5 ms.

Until recently, IPL systems emitted relatively wide optical bands which generated up to 50% non-specific heating of tissue water by the longer, infrared wavelengths. The present dual mode filtering, which eliminates these wavelengths, allows for a more specific vascular treatment with less total energy delivered to the skin and hence leads to less adverse effects. This narrow-band filtering also eliminates the need for surface cooling.

Postoperative purpura is a well-known side effect after dye laser treatment for vascular lesions<sup>4</sup> and surface cooling reduces the purpura duration after pulsed dye laser treatments. Reis et al found a reduction in purpura dura-

tion of approximately a half-day using contact cooling,<sup>15</sup> and Fiskerstrand et al found a reduction from 13 days to 7.6 days using spray cooling.<sup>16</sup> Especially contact cooling with manual application and hence variable duration of the cold applicator on the skin may further make standardised treatments difficult. No skin cooling was used in the present study. Also, we did not observe any purpura, presumably due to the narrow-band dual mode filtering and longer pulse durations.

Except for a moderate hair reduction in hair-bearing skin, the IPL treatments were not associated with permanent adverse effects. This may be due to both the long pulse durations in the millisecond range, and to the use of relatively low fluency levels, which were comparable to those normally used with the frequency-doubled Nd:YAG laser.

Although the treatments were moderately painful, no patients required any anaesthesia during the treatments. Patients treated with the Nd:YAG laser normally require surface cooling due to the high absorption in epidermal melanin at 532 nm in order to salvage the epidermis and to reduce pain. The IPL used in the present study has a median wavelength of 705 nm, which generates less absorption in the melanin and better penetration of the epidermis. The combination of moderate melanin absorption and the large spot size of 10 × 48 mm seems to compensate for the relatively lower absorption in the haemoglobin target.

## Conclusions

The present study supports previous findings that the IPL is efficacious in the treatment of telangiectasias, and that narrow-band dual mode filtering further improves treatment safety. The only side effects associated with the treatment were transient erythema and oedema.

## References

1. Anderson RR, Parrish JA. Microvasculature can be selectively damaged using dye lasers: a basic theory and experimental evidence in human skin. *Lasers Surg Med* 1981; **1**: 263–76.
2. Tan OT, Murray S, Kurban AK. Action spectrum of vascular specific injury using pulsed irradiation. *J Invest Dermatol* 1989; **92**: 868–71.
3. Anderson RR, Parrish JA. Selective photothermolysis: precise microsurgery by selective absorption of pulsed radiation. *Science* 1983; **220**: 524–7.
4. Ross BS, Levine VJ, Ashinoff R. Laser treatment of acquired vascular lesions. *Dermatol Clin* 1997; **15**: 385–96.
5. Goldberg DJ. Laser treatment of vascular lesions. *Clin Plast Surg* 2000; **27**: 173–80.
6. Kienle A, Hibst R. A new optimal wavelength for treatment of port wine stains? *Phys Med Biol* 1995; **40**: 1559–76.
7. Fiskerstrand EJ, Svaasand LO, Kopstad G et al. Laser treatment of port wine stains: therapeutic outcome in relation to morphological parameters. *Br J Dermatol* 1996; **134**: 1039–43.
8. Dierickx CC, Casparian JM, Venugopalan V et al. Thermal relaxation of port-wine stain vessels probed in vivo: the need for 1–10-millisecond laser pulse treatment. *J Invest Dermatol* 1995; **105**: 709–14.
9. Dover JS, Arndt KA. New approaches to the treatment of vascular lesions. *Lasers Surg Med* 2000; **26**: 158–63.
10. Raulin C, Weiss RA, Schonemark MP. Treatment of essential telangiectasias with an intense pulsed light source. *Dermatol Surg* 1997; **23**: 941–5.
11. Schroeter CA, Neumann HA. An intense light source. The photoderm VL-flashlamp as a new treatment possibility for vascular skin lesions. *Dermatol Surg* 1998; **24**: 743–8.
12. Raulin C, Schroeter C, Maushagen-Schnaas E. Treatment possibilities with a high-energy pulsed light source. *Hautartz* 1997; **48**: 886–93.
13. Goldman MP, Eckhouser S. Photothermal sclerosis of leg veins. ESC Medical Systems, LTD Photoderm VL Cooperative Study Group. *Dermatol Surg* 1996; **22**: 323–30.
14. Dummer R, Graf P, Greif C, Burg G. Treatment of vascular lesions using the VersaPulse variable pulse width frequency doubled neodymium:YAG laser. *Dermatology* 1998; **197**: 158–61.
15. Reis WR, Speyer MT, Rienisch L. Effect of thermal conduction media on skin surface during laser irradiation. *Laryngoscope* 2000; **110**: 575–84.
16. Fiskerstrand EJ, Ryggen K, Norvang LT, Svaasand LO. Clinical effects of dynamic cooling during pulsed laser treatment of port-wine stains. *Lasers Med Sci* 1997; **12**: 320–7.

